

● *Original Contribution*

ECHOGENIC REGIONAL ANAESTHESIA NEEDLES: A COMPARISON STUDY IN THIEL CADAVERS¹

SHUO GUO,* ANDREAS SCHWAB,† GRAEME MCLEOD,‡ GEORGE CORNER,†
SANDY COCHRAN,§ ROOS EISMA,|| and ROGER SOAMES||

*Institute for Medical Science and Technology, University of Dundee, Dundee, Scotland, UK; †Department of Medical Physics, Ninewells Hospital and Medical School, Dundee, Scotland, UK; ‡Institute of Academic Anaesthesia, University of Dundee, Dundee, Scotland, UK; §Institute for Medical Science and Technology, University of Dundee, Dundee, Scotland, UK; and ||Centre for Anatomy and Human Identification, University of Dundee, Dundee, Scotland, UK

(Received 3 August 2011; revised 22 November 2011; in final form 1 January 2012)

Abstract—Ultrasound guidance is now the standard procedure for regional nerve block in anesthesiology. However, ultrasonic visualisation of needle manipulation and guidance within tissues remains a problem. Two new echogenic needles (Pajunk and Braun) have been introduced to anesthesiology clinical practice but evaluation has been restricted to preserved animal tissue. In this study, the visibility of both echogenic needles was compared with a standard nonechogenic needle in a Thiel cadaver model. A total of 144 intramuscular injections were made in the upper arm in-plane and out-of-plane to the ultrasound beam at four angles (30°, 45°, 60° and 75°). The visibility of the needle was assessed by two independent, blinded observers using a 5-point Likert ordinal scale. Weighted κ for interobserver agreement was 0.77 (95% confidence interval [CI]: 0.68–0.86). The Pajunk echogenic needle was more visible than the Braun standard needle in-plane ($p = 0.04$), and the Braun standard and Braun echogenic needles out-of-plane ($p = 0.02$). Independent predictors of visibility using logistic regression were needle ($p < 0.001$) and plane of insertion ($p = 0.08$), receiver operator characteristic (ROC) area under the curve 0.90. In conclusion, the Pajunk echogenic needle offers the best visibility for ultrasound-guided regional anesthesia. (E-mail: g.a.mcleod@dundee.ac.uk) © 2012 World Federation for Ultrasound in Medicine & Biology.

Key Words: Ultrasound, Thiel, Cadaver, Anesthesia, Regional, Needle.

INTRODUCTION

Anesthesia for peripheral limb surgery is increasingly performed using local anesthetic nerve blocks: patients with chronic respiratory or cardiac disease may be kept awake during surgery without resorting to general anesthesia. The percutaneous application of local anesthetic around nerves using ultrasound and fine needles is often described as ultrasound guided regional anesthesia (UGRA). The primary advantage of this approach is that patients may be fed and rehabilitated quickly, improving postoperative functional recovery. Although ultrasound technology and clinical experience of ultrasound guided regional anesthesia have grown, ultrasonic needle visualization and guidance within tissues still

remain difficult, particularly when performing regional blocks out-of-plane in the elderly and obese. Considering such issues, with the reported incidence of nerve damage between 0.03% and 2.8% (Brull et al. 2007), intraneural injection may lead to permanent nerve damage and loss of function. This illustrates the importance of anaesthetists being able to visualise needles with orientations both in-plane and out-of-plane to the ultrasound beam.

Previous modifications to needles include incorporation of a polymer coating (Culp et al. 2000), mechanical guides (Phal et al. 2005), optic guides (Tsui 2007), internal stylets (Cockburn and Cosgrove. 1995), micro-bubbles (Swenson et al. 2008), guidewires (Schafhalter-Zoppoth et al. 2004) and use of software algorithms (Cheung and Rohling 2004) to enhance needle visibility. None, however, has proven entirely successful nor commercially successful. Two recent innovations are the Mitchell “echogenic needle” from Pajunk, (Pajunk, Newcastle upon Tyne, UK), an intermittently-textured needle (Deam et al. 2007), and the Braun “echogenic” needle, a smooth-surfaced needle (B.Braun, Sheffield, UK).

Address correspondence to: Graeme McLeod, Institute of Academic Anaesthesia, University of Dundee, Centre for Neuroscience, Division of Medical Sciences, Ninewells Hospital and Medical School, Mailbox 8, Dundee, DD1 9SY, Scotland, UK. E-mail: g.a.mcleod@dundee.ac.uk

¹Presented at Anesthetic Research Society, Nottingham 2010.

Studies reported to date have been conducted in water baths, synthetic phantoms (Schafhalter-Zoppoth *et al.* 2004; Deam *et al.* 2007), preserved animal phantoms (Deam *et al.* 2007; Maecken *et al.* 2007) and fresh cadavers (Maecken *et al.* 2007); however, each has its limitations. Phantoms do not have exactly the same echogenic characteristics as humans, they do not replicate detailed anatomy and they can entrap air along the needle path during intervention. Fresh frozen cadavers have a very restricted lifespan, present an infection risk and do not permit extensive studies to be performed over time.

The Centre for Anatomy and Human Identification (CAHId), University of Dundee was the first unit in the United Kingdom to prepare cadavers embalmed with the Thiel process, using a novel biocidal preservation technique, which has proven to be a successful surgical and anaesthetic model. The Thiel cadaver has recently been assessed (McLeod *et al.* 2010) and shown realistic, high quality ultrasound images, full rotation of limbs, ready identification and tracing of peripheral nerves, spread of solution and recognisable intraneural injection. In view of the potential benefits of the Thiel model, it was decided to compare the visibility of the standard regional needle (Braun standard) and the two echogenic needles recently introduced by Braun and Pajunk (Fig. 1).

METHODS

The study was undertaken at CAHId, University of Dundee. All ultrasound scans were conducted by a single operator over the upper arm muscles (biceps, triceps and deltoid) of both arms using a Zonare Z. One ultrasound imaging system (Zonare, Mountain View, CA, USA) and a 5–10 MHz linear ultrasound probe. Image quality was standardised by utilizing the optimization facility on the ultrasound machine after the probe was applied to the cadaver and before needles were injected and videos recorded. Angulation was standardised with a machined plastic guide, cut at four angles, 30°, 45°, 60° and 75° (Fig. 2). Although the narrow width of the ultrasound beam can make it difficult to maintain visibility as the needle is inserted, the design of the engineered guide ensured that the needle was held firmly with inadvertent movement outwith the beam minimised.

A statistical block randomisation was performed using computer software (randomization.com) for the in-plane and out-of-plane injections. Statistical blocks contained 12 units, *i.e.*, four angles (30°, 45°, 60° and 75°) and three needles (Braun standard, Braun echogenic, Pajunk echogenic). Needle injection was standardised by inserting the needle 3 cm below the skin into muscle, retracting the needle to just below the skin, then reinserting to 3 cm. All needle passes were recorded onto video,

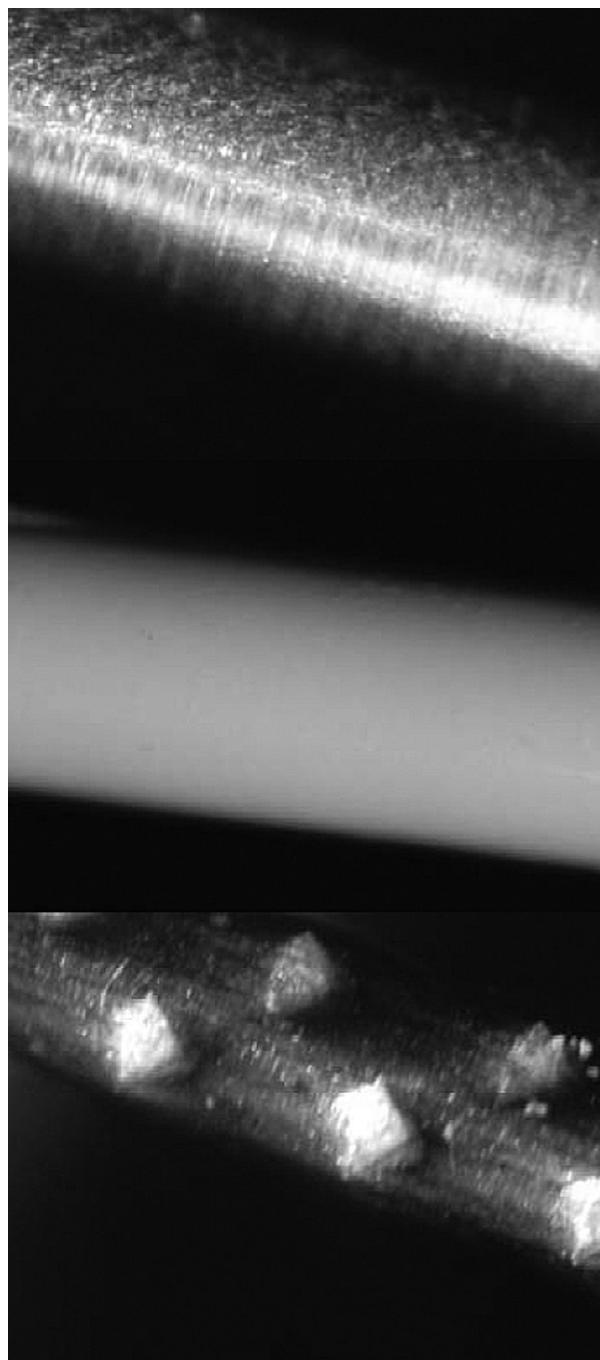


Fig. 1. Microscopic image of in order from top to bottom: Pajunk nonechogenic; Braun echogenic; and Pajunk echogenic needles.

retrospectively downloaded by the engineer and analysed by two independent raters blinded to angle and plane of injection.

The primary endpoint of the study was the mean rater 5-point Likert score (0 = very poor, 1 = poor, 2 = fair, 4 = good, 5 = very good) for needle visibility as assessed by two independent anaesthetic raters. The




Fig. 2. Engineered blocks with angles of 30°, 45°, 60° and 75°.

mean visibility score was used for analysis. For the purposes of this study, the angle of needle entry was defined as the angle between the ultrasound beam and the surface of the needle.

Data was used to determine the secondary end point of the study, namely independent predictors of good visibility using logistic regression analysis. The rationale for using a regression model is that use of three covariates (angle, needle and plane) in this study makes it difficult to determine how much “weight” or influence each covariate has on “good” visibility; whether this relationship is linear or nonlinear; and whether there is an interdependency or interaction between covariates which best predicts the model. Comparison of number of visible needles and actual probability of good visibility was calculated using the logistic function [eqn (1)]:

$$f(z) = \frac{e^z}{e^z + 1} = \frac{1}{1 + e^{-z}} \quad (1)$$

$$z = \beta_0 + \beta_1 x_1 + \beta_2 x_2 + \beta_3 x_3 + \dots + \beta_k x_k, \quad (2)$$

$f(z)$ is the probability of a specific outcome between 0 and 1. The variable z is the addition of all independent variables in the model; e is a number approximate to 2.71828; β_1, β_2 , etc are regression coefficients of x_1, x_2 , etc. The intercept β_0 is the value of z when the value of all independent variables are zero (Harrell 2001).

A mean visibility score between raters of 4 or 5 defined good visibility and scores of 1, 2 and 3 defined very poor to fair visibility. Internal model validation was performed by software randomly selecting 62.5% of data (90 measurements) for model development and 37.5% for validation. The Hosmer–Lemeshow test was used to test the goodness of fit of the logistic regression model and discrimination quantified by the area under the receiver operating characteristic (ROC) curve, plotting sensitivity against 1-specificity. Statistical packages included PASW Statistics 18 (IBM, Portsmouth, UK)

and NCSS (NCSS, Kaysville, UT, USA). Needles were photographed with a Meiji Metko MT 7000 metallurgical microscope (Meiji Metko, Axbridge, UK).

RESULTS

Pilot study

An initial pilot study was conducted. Forty-eight intramuscular needle injections were performed in-plane and out-of-plane at four angles (30°, 45°, 60° and 75°) using each of the three needles. The pilot study showed a nonparametric distribution of data using the Shapiro-Wilk test. Median visibility scores were higher for the Pajunk echogenic needle when inserted at 75° out-of-plane and 30° in-plane. With this data an effect size of 0.47 for “needle” and an effect size of 0.43 for “angle”, $\alpha = 0.5$, $\beta = 0.2$, was calculated. Using a randomized statistical block analysis of variance (ANOVA) power analysis (PASS; NCSS, Kaysville, UT, USA), we required a total of six statistical blocks, *i.e.*, 72 injections in-plane and 72 injections out-of-plane, were required.

Main study

For the main study, a total of 144 injections were made as per protocol. Weighted κ for interobserver agreement was 0.77 (95%CI: 0.68–0.86).

There were 11 Likert visibility scores of 4 or 5 and 133 with Likert scores of 1, 2 or 3. Covariates associated with Likert score 4 or 5 were Pajunk echogenic needle ($n = 11$); needle angle (30° $n = 3$, 45° $n = 4$, 75° $n = 4$; in-plane insertion ($n = 8$) and out-of-plane insertion ($n = 3$).

In-plane (Fig. 3), the median visibility scores were 1, 1 and 3 for the Braun standard (Fig. 4), Braun echogenic (Fig. 5) and Pajunk echogenic needles (Fig. 6), respectively, Friedman’s $Q = 6.50$, $p = 0.04$. *Post hoc* tests showed a difference between the Braun standard and Pajunk echogenic needles.

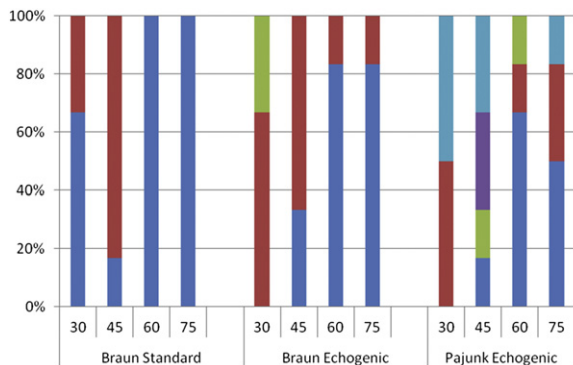


Fig. 3. Results of in-plane needle insertion: percentage of images at with visibility scores from very poor (1) to very good (5) using Likert scale. Graph categorizes data according to angle (30°, 45°, 60° and 75°) and needle.

Out-of-plane (Fig. 7), the median visibility scores were 1, 1 and 3 for the Braun standard, Braun echogenic and Pajunk echogenic needles, respectively, Friedman’s Q 7.50, $p = 0.02$. *Post hoc* tests showed a difference between the Pajunk echogenic and both the Braun standard and Braun echogenic needles.

Logistic model

Univariate logistic regression analysis showed that the angle of needle insertion contributed little to the overall model and was discarded from model calculations. Multivariate logistic regression analysis showed that type of needle (χ^2 26.5, $p < 0.001$) and plane of insertion (χ^2 3.0, $p = 0.08$) were independent predictors of good visibility. There was no interaction between each covariate ($p = 0.99$) and a simple one-way model was required. The area under the ROC curve for prediction of good visibility using this model was 0.90 (Fig. 8) and the

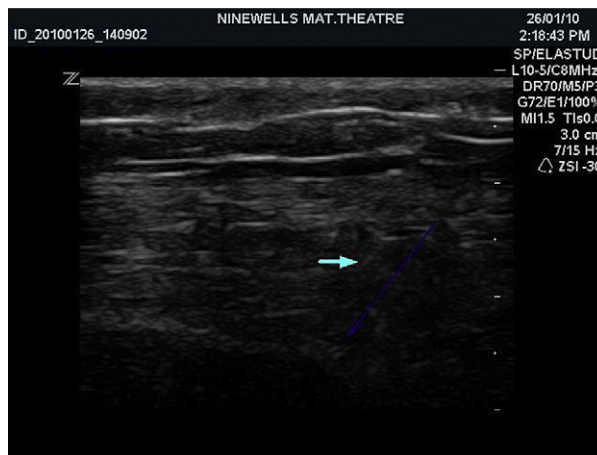


Fig. 5. Example of Braun echogenic needle inserted at 45°.

Hosmer and Lemeshow test χ^2 0.0, $p = 1.0$, indicated a good model fit.

DISCUSSION

This study has found that the Pajunk echogenic needle is more visible than the Braun standard needle in-plane and more visible than both the Braun standard and Braun echogenic needles when out-of-plane. Independent predictors of good visibility were use of (1) the in-plane approach and (2) the Pajunk echogenic needle.

Many anesthesiologists remain uneasy about manipulating needles under ultrasound guidance. There is a pressing need for the development of needles suitable for the UGRA beginner to build confidence and develop skills to develop the higher competences associated with regional anaesthesia experts. It has been shown in this study that the Pajunk echogenic needle performs better than both Braun needles in both ultrasound planes

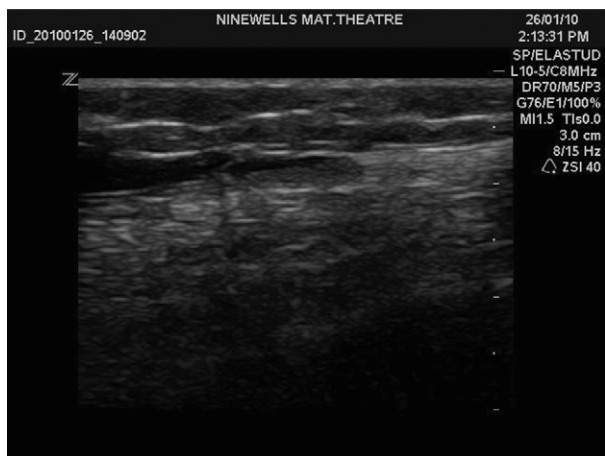

Fig. 4. Example of Pajunk nonechogenic needle inserted at 45°. Needle not visible.

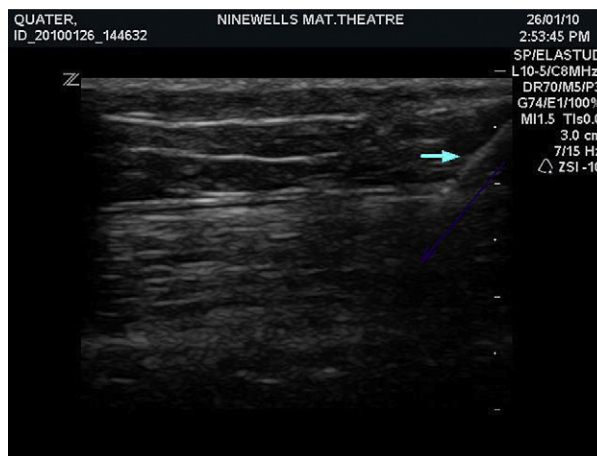


Fig. 6. Example of Pajunk echogenic needle inserted in-plane at 45°.

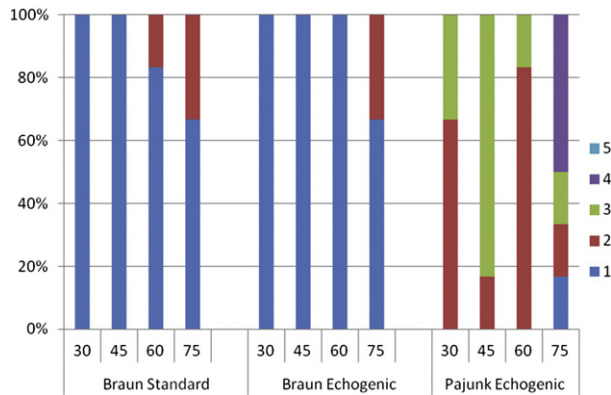


Fig. 7. Results of out-of-plane needle insertion: percentage of images at with visibility scores from very poor (1) to very good (5) using Likert scale. Graph categorizes data according to angle (30°, 45°, 60° and 75°) and needle.

and should be helpful to new users. However, the median score for visibility of the Pajunk echogenic needle was still only 3 and only 11 needle tests out of 144 recorded Likert visibility scores of 4 or 5.

Better visibility may be accounted for by the radical new design of the Pajunk echogenic needle (Fig. 1). Multiple, flat, angled surfaces orientated around the needle allow reflection irrespective of angle of orientation. Because some of these reflections are in the direction of the transducer, more waves are returned to the probe. Interestingly, the Braun echogenic needle has a similar design but insulated by a white coating, yet it failed to offer the same visibility as the Pajunk echogenic needle when inserted out-of-plane. A possible reason may be that the white coating diffuses ultrasound energy in all directions and a lower intensity of energy is returned back to the transducer. Similarly, the polished nonecho-

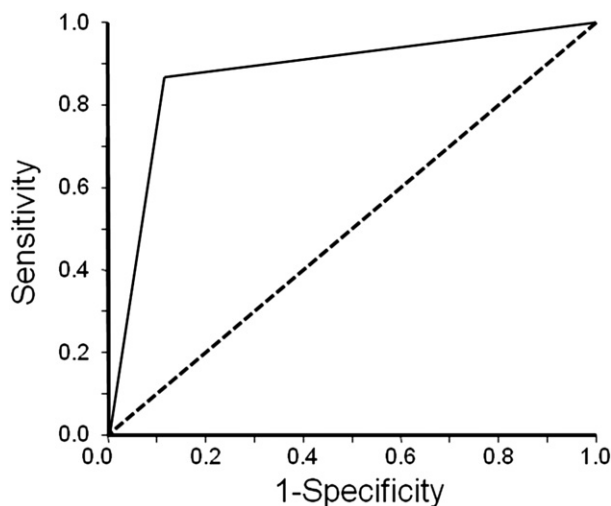


Fig. 8. Receiver operator characteristic (ROC) curve for prediction of visibility area under the curve (AUC) = 0.90.

genic Touhy needle acts as a reflector and, unless the needle is at an angle approaching right angles to the isonating beam, directs the reflected waves away from the transducer. All this suggests that these needles represent an improvement in needle visibility but further developments are required before improved visibility is obtained in the majority of cases.

The results confirm clinical observations that needle visibility is better using the in-plane approach. Although clinical experience suggests that out-of-plane techniques are no more difficult than in-plane techniques for experienced regional anaesthetists, novices may need reassurance that the needle tip is adjacent to the intended nerve and that nerve injury is unlikely. Nevertheless, even in-plane, 50% of Pajunk echogenic needle tests had poor visibility and we can only speculate why this should be so. For this reason it is recommended that standard procedures, such as cautious insertion, hydrolocation test doses using 0.5 to 1 mL of solution and gentle manipulation of tissues, remain a mainstay of clinical practice rather than reliance on observation of the needle.

Although increased specular reflection from multiple surfaces probably accounts for the better visibility of echogenic needles, it is also important that experimental conditions are taken into account. Thiel cadavers are prepared by immersion within a tank containing boric acid and salts, thus, retaining salt and water, providing potentially good conditions for ultrasound scanning. However, reflection of ultrasound from nerves and muscles in elderly patients (the group who donate their bodies to medical research) is poorer than in younger patients and excellent resolution of structures is often difficult to obtain in clinical practice.

New developments include the clinical introduction of Enhanced Needle Visualization® technology (SonoSite Inc., Bothell, WA, USA) using image processing but no studies to our knowledge have been conducted comparing echogenic needles. Our group is currently developing preprocessing algorithms for needle visualization.

The Thiel model was utilised to test the needles in a safe environment closely replicating human anatomy *in vivo*. The embalming mixture, initially devised by Professor Thiel at the Medical University of Graz, Austria (Thiel 1992) is a water-based mixture of salts and acids, glycol and chlorocresol with biocidal properties, minimising exposure to carcinogenic compounds such as formaldehyde, which is only present in low concentrations in the Thiel fluids, and phenol, which is not used at all. The cadavers are preserved with life-like flexibility and realistic tissue colour and texture. This preservation is viable in the long term, which allows multiple uses of the cadavers, increasing availability and reducing costs.

Ideally, we wish to assess the visibility of needles in patients, but the nature of this experiment performed on 144 occasions does preclude human study. Funding councils in the UK are encouraging translational medical research before human study, and use of Thiel cadavers offered us the opportunity to conduct this study in a stable environment. We conducted the study on a single cadaver because Thiel cadaver availability is restricted until our new facility opens next summer. Then, we intend to conduct studies on several Thiels to document variability, then progress to human studies powered by data from cadavers. Our experience suggests that development of new medical devices using Thiel cadavers, before introduction into clinical use, may reduce the need for animal testing and allow non-clinically trained staff to be involved in procedures, increasing mutual understanding between technical and clinical staff.

Thiel cadavers have been used successfully to simulate neurosurgery (Bregy *et al.* 2008) laparoscopic (Giger *et al.* 2008) and plastic surgery (Wolff *et al.* 2008). One study (Benkhadra *et al.* 2009) compared the suitability of fresh and Thiel bodies for UGRA of the cervical region: this remains the only publication out with our group (McLeod *et al.* 2010) describing such procedures in this cadaver model. The Thiel cadaver model is already used in the University of Dundee for post-fellowship anaesthetic regional anaesthesia and surgical training courses (Eisma *et al.* 2011) and as a platform for medical engineering projects at the Institute for Medical Science and Technology using Angiography and MRI.

In conclusion, the present study has found that the Pajunk echogenic needle is more visible than the Braun standard needle in-plane and more visible than both the Braun standard and Braun echogenic needles when out-of-plane.

REFERENCES

- Benkhadra M, Faust A, Ladoire S, Trost O, Trouilloud P, Girard C, Anderhuber F, Feigl G. Comparison of fresh and Thiel's embalmed cadavers according to the suitability for ultrasound-guided regional anaesthesia of the cervical region. *Surg Radiol Anat* 2009;31:531–535.
- Bregy A, Alfieri A, Demertzis S, Mordasini P, Jetzer AK, Kuhlen D, Schaffner T, Dacey R, Steiger HJ, Reinert M. Automated end-to-side anastomosis to the middle cerebral artery: A feasibility study. *J Neurosurg* 2008;108:567–574.
- Brull R, McCartney CJ, Chan VW, El-Beheiry H. Neurological complications after regional anesthesia: Contemporary estimates of risk. *Anesth Analg* 2007;104:965–974.
- Cheung S, Rohling R. Enhancement of needle visibility in ultrasound-guided percutaneous procedures. *Ultrasound Med Biol* 2004;30:617–624.
- Cockburn JF, Cosgrove DO. Device to enhance visibility of needle or catheter tip at color Doppler US. *Radiology* 1995;195:570–572.
- Culp WC, McCowan TC, Goertzen TC, Habbe TG, Hummel MM, LeVeen RF, Anderson JC. Relative ultrasonographic echogenicity of standard, dimpled, and polymeric-coated needles. *J Vasc Interv Radiol* 2000;11:351–358.
- Deam RK, Kluger R, Barrington MJ, McCutcheon CA. Investigation of a new echogenic needle for use with ultrasound peripheral nerve blocks. *Anaesth Intensive Care* 2007;35:582–586.
- Eisma R, Mahendran S, Majumdar S, Smith D, Soames RW. A comparison of Thiel and formalin embalmed cadavers for thyroid surgery training. *Surgeon* 2011;9:142–146.
- Giger U, Fresard I, Hafliger A, Bergmann M, Krahenbuhl L. Laparoscopic training on Thiel human cadavers: A model to teach advanced laparoscopic procedures. *Surg Endosc* 2008;22:901–906.
- Harrell F. Regression modeling strategies: With applications to linear models, logistic regression, and survival analysis. Springer series in statistics 2001. New York: Springer Verlag, New York.
- Maecken T, Zenz M, Grau T. Ultrasound characteristics of needles for regional anesthesia. *Reg Anesth Pain Med* 2007;32:440–447.
- McLeod G, Eisma R, Schwab A, Corner G, Soames R, Cochran S. An evaluation of the Thiel-embalmed cadavers for ultrasound based regional anaesthesia training and research. *Ultrasound* 2010;18:125–129.
- Phal PM, Brooks DM, Wolfe R. Sonographically guided biopsy of focal lesions: A comparison of freehand and probe-guided techniques using a phantom. *AJR Am J Roentgenol* 2005;184:1652–1656.
- Swenson JD, Davis JJ, DeCou JA. A novel approach for assessing catheter position after ultrasound-guided placement of continuous interscalene block. *Anesth Analg* 2008;106:1015–1016.
- Schafhalter-Zoppoth I, McCulloch CE, Gray AT. Ultrasound visibility of needles used for regional nerve block: An *in vitro* study. *Reg Anesth Pain Med* 2004;29:480–488.
- Thiel W. The preservation of the whole corpse with natural color. *Ann Anat* 1992;174:185–195.
- Tsui BC. Facilitating needle alignment in-plane to an ultrasound beam using a portable laser unit. *Reg Anesth Pain Med* 2007;32:84–88.
- Wolff KD, Kesting M, Mucke T, Rau A, Holzle F. Thiel embalming technique: A valuable method for microvascular exercise and teaching of flap raising. *Microsurgery* 2008;28:273–278.